

Cessation of Dreaming with Posterior Cortical Lesions: A Clinicoanatomical Study

Malini Mohana

Department of Psychology

University of Cape Town

Supervisor: Mark Solms

Word count

Abstract: 191

Main body: 8276

ABSTRACT

A review of the current literature shows that the posterior cortical regions involved in dream generation have not yet been conclusively established. Classical studies in this field have concluded that heteromodal (global) and unimodal (visual-specific) loss of dreaming is attributed to a single over-arching neurological syndrome – Charcot-Wilbrand Syndrome – that is caused by lesions of the posterior cortex. Yet more recent contrasting studies exist that have shown that damage to this area does not necessarily result in dream loss. To contribute to the understanding of the specific regions involved in the generation of dreams, neuro-imaging methods were used to assess whether heteromodal (global) loss of dreaming can occur with Posterior Cerebral Artery (PCA) lesions. Five patients with the relevant lesions were analysed and discussed in a multi-case study. Results showed that this study supported the hypothesis that lesion sites will be different between cases with medial-occipito-temporal lesions in which dreaming is preserved or global loss of dreaming occurs. Analysis showed that participants with global loss of dreaming occur with both more *posterior bilateral* occipital-temporal lesions as well as thalamic damage, whereas dreaming participants showed only unilateral damage to the relevant posterior lesions.

Key words: dreaming; global cessation of dreaming; posterior cerebral artery lesion

CESSATION OF DREAMING WITH POSTERIOR CORTICAL LESIONS: A CLINICOANATOMICAL STUDY

Introduction

It is widely acknowledged that dream loss can occur as a result of brain damage (Dorrichi & Violani 1992, Solms 1997). The neurological process of dreaming is one that has been explored and debated over many decades. Numerous reports in current literature present a substantial body of evidence which suggest that the dreaming experience is powerfully affected by neurological disease (Charcot, 1883; Wilbrand, 1887; Murri et al, 1984; Cathala et al, 1983; Dorrichi & Violani 1992; Solms, 1997, 2000). Yet the neurological correlates of the loss of dreaming continue to puzzle scientists. Analysis of neurological cases presenting with dream loss has generally been attributed to the concept of Charcot-Wilbrand Syndrome (CWS), in which heteromodal (global) loss of dreaming and unimodal (visual-specific) loss of dreaming are grouped under the same heading. Solms' (1997) and Yu's (2001) argument against this conflation of the two above mentioned syndromes resulted in the theory that lateral occipito-temporal lesions result in global loss of dreaming, while medial occipito-temporal lesions result in visual-deficit dreaming. However, a case report of global cessation of dreaming, with medial occipito-temporal damage, casts doubt on this revision of the CWS (Bischoff & Bassetti, 2006).

Evidently, the neurological inability to dream has been a subject of uncertainty. This study will attempt to uncover a neurological correlate for loss of dreaming by way of multi-case analysis.

Charcot-Wilbrand Syndrome

The possibility that dreaming could be impacted by brain injury was first recorded more than 100 years ago by Charcot in 1883. His unusual case report featured a patient (Monsieur X) who had lost his visual memories of shapes and colour, and found that familiar things around him appeared new and strange. As such he lacked the ability to conjure up any mental images (*irreminiscence*) and recognise familiar faces (*prosopagnosia*). Monsieur X's inability to visualise extended to his dreaming state as well, and although he continued to dream, his dreams were non-visual and comprised "simply of speech" (Solms, Kaplan-Solms & Brown, 1996, p.158). This classical case never came to autopsy.

Following Charcot's case, Wilbrand (1887) reported a similar case in which his

patient (Fraulein G) suffered an abrupt loss of consciousness. After recovering consciousness in the hospital several hours later she was unable to visually recognise anyone. This loss of recognition continued for several weeks. Even though she was regarded as blind by all those around her, she maintained that she was not completely blind and spoke of being able to see a table cloth “with the blue border spread out on the table in the sick room” (Solms, Kaplan-Solms & Brown, 1996, p. 90). Everything she saw seemed unfamiliar and she would frequently mistake one object or person for another. It is important to note that she still retained the ability to vividly visualise mental images at will, but could not recognise objects through the visual sense (*visual agnosia*). Another key symptom was her inability to dream (Solms, Kaplan-Solms & Brown, 1996). However, 10 years after her hospitalization she reported seeing the image of her late sister in a dream. This case came to autopsy (Wilbrand, 1891), revealing that Fraulein G had suffered bilateral infarction in the occipito-temporal region.

Together these two classical case reports form the foundation for what came to be known as the concept of Charcot-Wilbrand Syndrome (CWS). The earliest definition in secondary literature defined the syndrome as “mind-blindedness with disturbance of optic imagination” (Potzl, 1928, p. 306). Following this, it was later defined by Nielsen (1946) as the inability to revisualise images, and by Critchley (1953) as a symptom whereby a patient loses the ability to conjure up visual memories or images and ceases to dream completely. Among the more recent definitions of CWS by Murri et al (1984, p. 185) reads: “the association of loss of the ability to conjure up visual images or memories and loss of dreaming...[indicating] a lesion in the acute phase affecting the posterior regions”. The most recent definition by Bischoff and Bassetti (2004) described CWS as the association of dream loss with visual irremembrance (the inability to visualise mental images), prosopagnosia (the inability to recognise faces) and topographagnosia (disorder of orientation in familiar surroundings). Evidently, this syndrome was characterised by loss — or gross reduction — of dreaming and has traditionally focused on deficits in visual imagery and dreams.

Charcot-Wilbrand Syndrome Revised

In the original literature, the nosological heading ‘Charcot-Wilbrand Syndrome’ encompassed both Charcot and Wilbrand’s cases, as its name suggests. However, although both cases suffered from some form of visual impairment it is evident that there are considerable differences in the symptoms. Wilbrand’s (1887) case suffered mainly from impairment in visual recognition (visual agnosia) while Charcot’s (1883) case suffered

mainly from an impairment of visual imagery (irreminiscence). Although Charcot's case did feature some impairment in recognition, this was limited to a sense of 'unfamiliarity'. It was his inner vision, not visual perception that was dramatically affected. In Wilbrand's case the opposite applied; she retained vivid visual mental imagery but was severely agnosic, to the point of initially being considered blind. More importantly, Charcot's case still experienced dreaming, albeit restricted to non-visual features, while Wilbrand's case ceased to dream completely.

Heteromodal and Unimodal Visual Cortices in Dreaming

Therefore, Solms, Kaplan-Solms and Brown (1996) and Solms (1997) argued that the Charcot-Wilbrand syndrome is a nosological flaw, and that it is in fact a conflation of two different syndromes: (a) heteromodal (global) loss of dreaming and (b) unimodal (visual-specific) loss of dreaming. They pointed out that Wilbrand's and Charcot's cases corresponded to these two types respectively. In other words, Wilbrand's case ceased to dream *completely* while Charcot's case retained the ability to dream, albeit restricted to verbal features. They also pointed out that unimodal (visual-specific) loss of dreaming was associated with irreminiscence whereas heteromodal (global) loss of dreaming was not.

Solms then studied an unselected series of 361 cases and identified 2 cases of unimodal (visual-specific) loss of dreaming and 112 cases of heteromodal (global) loss of dreaming. He confirmed that there were indeed two different types of 'Charcot-Wilbrand' syndrome, and he observed that unimodal (visual-specific) loss of dreaming was associated with medial occipito-temporal lesions, whereas heteromodal (global) loss of dreaming was associated with a lateral inferior parietal lesion. That is, unimodal (visual-specific) loss of dreaming was associated with a lesion in unimodal association cortex whereas heteromodal (global) loss of dreaming seemed to be associated with a lesion in heteromodal association cortex. This corresponded with the fact that in his unimodal (visual deficit) loss of dreaming cases, like all those reported in the previous literature, the unimodal loss of dreaming was associated with a corresponding unimodal loss of waking visual imagery (irreminiscence). This was not true of the heteromodal (global) loss of dreaming cases, in whom irreminiscence was reported in only 2.7 % of cases.

In the light of these findings, and in line with the current literature on mental imagery (Kosslyn, 1994), Solms argued that dreams are 'backwardly projected' onto the posterior cortex, reversing the normal hierarchy of visual processing, from heteromodal to unimodal association cortices. In other words dreams are initiated by higher order association areas,

which are then visually represented in the modality-specific visual association areas. Specifically, the Solms' analysis of these lesion studies initially converged on the theory that damage to the inferior parietal lobule (Brodmann's areas 39 and 40, on the lateral surface of either hemisphere) results in the loss of dreaming (Solms, 1997).

However, a major problem with Solms's conclusions came to light with the appearance of PET imaging studies of the dreaming brain. Here, the dreaming brain is operationalised for the purposes of such studies as the REM (Rapid Eye Movement)¹ brain on the basis of the fact that 90% of awakenings from REM produce dream reports, versus 10% of awakenings from NREM (Non-Rapid Eye Movement) sleep. Although these PET studies were completely compatible with the lesion evidence in every other respect, they consistently showed that the inferior parietal lobule was deactivated during dreaming sleep (Heiss, Pawlik, Herholz, Wager & Wienhard, 1985; Maquet et al., 1990; Madsen et al., 1991; Hong, Gillin, Dow, Wu & Buchsbaum, 1995; Maquet et al., 1996; Nofzinger, Mintun, Wiseman, Kupfer & Moore, 1997; Braun et al., 1997; Braun et al., 1998). It was therefore difficult to imagine how heteromodal (global) loss of dreaming could be attributed to this lesion site.

As mentioned above, Solms (1997) had claimed on the basis of his own series of cases that heteromodal (global) loss of dreaming was attributable to a lesion in BA 39 or 40. In light of the PET literature, Yu (2001) re-analysed the original data. He observed that 90.5 % of Solms's non-dreaming patients with inferior parietal damage BA 39 and 40 had also sustained damage to the contiguous occipital-temporal regions BA 19, 22 and 37. Based on this observation, combined with the imagery literature, Yu concluded that lateral occipito-temporal lesions (and not parietal ones) were responsible for type (a) loss of dreaming.

Analysis of posterior lesion studies indicates that occipito-temporal lesions *generally* result in the global cessation of dreaming. In Yu's (2001) meta-analysis he observed that there were three non-dreaming patients whose lesions were purely in the occipito temporal region. Lesions to BA40 occurred in 60% of the sample, but the same frequency was also found in the superior temporal gyrus of the occipito-temporal cortex (BA22). In addition, the temporo-occipital junction (BA37) also produced a high frequency in both Solms' record (40%) and previous literature (16.4%) (Yu, 2001). Brodmann's area 19, which is involved in visual association in the occipital lobe, along with the thalamus, were also implicated, with a frequency of 22.9% and 28.6% respectively (Table 1).

¹ Rapid eye movement sleep (REM) is characterised by bursts of rapid eye movement and physiological changes that include atonia and heightened cerebral cortical activation similar to that of the waking state (Aserinsky & Kleitman, 1953)

Analysis of previous literature produces a similar trend: twice the number of cases with occipito-temporal lesions, relative to parietal-temporal lesions and parietal-occipital lesions, presented with global cessation of dreaming (Table 2).

Table 1

Cytoarchitectonic Data of Highest Frequency of Global Cessation of Dreaming in Patients with Posterior Cortical Lesions (N=35)

Localisation	Substructures	Left	Right	Total %
Occipital	BA18	3	1	11.4%
	BA19	5	3	22.9%
Temporal	BA22	10	11	60%
	BA37	6	8	40%
Parietal	BA39	3	6	28.6%
	BA40	8	12	60%
Thalamus		5	5	28.6%

Note. The cytoarchitectonic regions of highest frequency in Solms' (1997) sample are listed above (Yu, 2001). The Brodmann's areas shown here do not constitute all the damaged areas in the sample, but those that are relevant for the purpose of this study

Table 2

Neuroanatomical Characteristics of Non-dreaming Clinical Cases Reported in the Previous Literature (N=61)

Localisation	Total %
Temporal	6.6
Occipital	9.8
Parietal	9.8
Parietal-Temporal	8.2
Parietal-Occipital	8.2
Occipito-Temporal	16.4

Dream Loss with Medial Occipito-Temporal Lesions

However, since Yu's above-mentioned investigations, two further cases of heteromodal (global) loss of dreaming have been reported in which the symptom was attributed to lesions in *medial* occipito-temporal cortex, that is, in the region that Solms (1997) had associated with unimodal (visual-specific) loss of dreaming. Bischoff & Bassetti (2004) reported a case of a 73-year old woman who reported total dream loss after a posterior cerebral artery (PCA) stroke. The stroke resulted in acute bilateral occipital damage, extending into the occipito-temporal region; this suggests that deep occipital lobe damage is involved in disrupted dream formation. Poza & Masso (2006) reported a case of a 24-year old man who suffered a unilateral left occipito-temporal injury. The patient experienced visual deficits and decreased motivation, and most importantly, total cessation of dreaming. In this case the lesion was said to be unilateral, and was reported as confirmation of Bischoff & Bassetti's report. In fact, since the pathology in this Poza & Masso case was an AVM, precise localising conclusions are not justified. However, in Bischoff & Bassetti's case the pathology was non-haemorrhagic thrombotic infarction (in the territory of the PCA). This pathology is ideal for localising purposes (Damasio & Damasio ref). In this new light, Wilbrand's (1887) case is clearly not unique. The aforementioned PET studies, Yu's (2001, 2003, 2007) analyses, as well as Bischoff & Bassetti's (2004) and Poza & Masso's (2006) cases, *all* of which featured damage to the occipito-temporal region, are testament to the recurring symptom hypothesised to be correlated with this area of damage – global cessation of dreaming.

Looking at the scan in Bischoff & Bassetti's case, the lesion appears to have been in BA17, 18, 37 and 19. This is certainly more consistent with the medial lesion site that Solms (1997) associated with unimodal (visual-specific) loss of dreaming than with the lateral lesion sites that either he or Yu had associated with heteromodal (global) loss of dreaming. However, Bischoff & Bassetti's case was unequivocally one of heteromodal (global) loss of dreaming: "our case demonstrates the existence of total dream loss as a distinct neuropsychological dysfunction after deep bilateral lobe damage, in the absence of REM sleep changes" (Bischoff & Bassetti, 2004, p. 586). Moreover, there was no mention of irremembrance in this case.

Bischoff & Bassetti's case therefore casts doubt on Solms's (1997) reformulation of the Charcot-Wilbrand Syndrome. At the very least, it casts doubt on his attribution of heteromodal (global) loss of dreaming to a lesion in lateral (heteromodal) association cortex and unimodal (visual-specific) loss of dreaming to a lesion in medial (unimodal visual) association cortex.

This doubt cast on Solms's (1997) reformulation of the Charcot-Wilbrand Syndrome, is magnified by a fact that has hitherto been overlooked. When Wilbrand's 1887 case came to autopsy, it was found that she had a bilateral medial occipito-temporal lesion (Wilbrand 1891). In other words, the prototypical heteromodal (global) loss of dreaming case had a lesion in the site that Solms (1997) associated with unimodal (visual-specific) loss of dreaming. Moreover, the lesion site and the pathology in Wilbrand's case was identical to that reported by Bischoff & Bassetti (2004): a bilateral thrombotic infarction in the territory of the PCA. Furthermore, unlike in Wilbrand's case, or in Solms (1997) series, or most previous cases reported in the extensive literature reviewed by Doricchi & Vilani (1992) and Solms (1997), the type (a) loss of dreaming in Bischoff & Bassetti's case was confirmed by sleep lab awakening.

Conclusion

It is evident from the literature that loss of dreaming is a subject of much dispute. Charcot-Wilbrand Syndrome lumps together both heteromodal (lateral) and unimodal (medial) loss of dreaming, while Solms' (1997) divided the two on the basis of modality; heteromodal cortices are involved in higher order processes and multiple sensory processes, thus lesions to this area could reasonably result in global cessation of dreaming. Yet both Bischoff and Bassetti (2004), Poza and Masso (2006) and the classical Wilbrand (1877) case indicates that unimodal damage can also result in global cessation of dreaming. Further studies are therefore necessary to differentiate between heteromodal loss of dreaming and unimodal loss of dreaming, in terms of precise localisation.

Rationale

The rationale of the present study is therefore the need to confirm that heteromodal (global) loss of dreaming can occur with lesions confined to the medial occipito-temporal region, and to establish the precise localization of the lesion responsible for this global loss by comparing dreaming and non-dreaming cases with lesions in this broad region.

Aims and Hypotheses

The aim of this research is firstly to study an unselected series of patients with the same pathology, in the same arterial field as reported in Bischoff & Bassetti's case: isolated thrombotic infarction in the territory of the PCA; and secondly, as Bischoff & Bassetti did, to confirm the dream phenomena (i.e. heteromodal dream loss, unimodal loss of dreaming, or preservation of dreaming) by sleep lab awakening.

H₁: type (a) loss of dreaming does occur with pure medial occipito-temporal lesions.

H₂ : the lesion site will be different in such cases from cases with medial occipito-temporal lesions in which dreaming is preserved or in which type (b) loss of dreaming occurs.

Methodology

Sample

All patients were selected by referral from neurological specialists at Groote Schuur Hospital and Gatesville Medical Centre, as part of a larger dream study being conducted at UCT by a masters student. Six participants were chosen based on their neuropathology and corresponding occipito-temporal lesions. Specifically, all patients suffered thrombotic infarctions in the posterior cerebral artery (PCA) territory, and presented with corresponding occipito-temporal damage. All patients were above the age of 18. Adult male and female participants, from any racial background, were included. The frequency of the dream experience of all participants, prior to their cerebrovascular accidents (CVA), was within the expected average i.e. a frequency of three or more dreams per week (Yu, 2007). The patients were divided into three groups, depending on whether they had global loss of dreaming, non-visual dreaming, or preservation of dreaming.

Group (a) Global loss of dreaming

This group consisted of patients who had experienced posterior cerebral artery (PCA) strokes and had corresponding unilateral or bilateral thrombotic infarctions in the occipito-temporal region. Thrombotic strokes are ideal for lesion studies as they are focal and circumscribed, and therefore create minimal confounding diffuse damage. The strict inclusion criterion for this group was that the patients had complete loss of dreaming following their strokes. This criterion was confirmed through the patients' subjective dream accounts, and verified in the sleep laboratory by awakening the patients during REM-sleep to ask whether or not they had been dreaming.

Group (b) Preservation of dreaming

This group consisted of three patients who had experienced posterior cerebral artery strokes and had corresponding, unilateral or bilateral, thrombotic infarctions in the occipito-temporal region. The strokes were focal and circumscribed. The strict inclusion criterion for the control group was that patients subjectively reported regular dreams. This was confirmed through the patients' subjective dream accounts, and verified in the sleep laboratory by REM-sleep awakenings in which they were asked whether or not they had been dreaming.

Exclusion criteria

Patients with haemorrhagic strokes were not included in the study, as these strokes result in widespread cerebral damage that cannot be accurately charted. Furthermore, the use of psychoactive drugs constituted an exclusion criterion, as narcotics have been shown to

affect dreaming. A general medical history was also conducted to make sure that none of the participants had a chronic medical condition that would affect their sleep e.g. epilepsy or asthma. Any participant with such a condition was excluded.

Materials

Neurology Reports

The participants' neurology reports were taken directly from their medical records, and their case information was duplicated in accordance with the APA guidelines for confidentiality and anonymity (American Psychiatric Association, 2005). The neurology reports provide accurate information regarding the medical history of the subject, the onset of the cerebral accident, and the date of neurological assessment. Furthermore, detailed summaries of clinical and neurological symptoms and complete interpretations of the MRI scans were also included in the neurological reports. The relevant medical information has not been distorted in any way, but all identifying information has been omitted.

Dream Recall

All participants were asked to provide subjective reports of whether they had continued to dream since the occurrence of their accident. Dream loss was confirmed by conducting semi-spontaneous nocturnal REM-sleep interviews, which were conducted according to polysomnograph (PSG) recordings.

Dream Interview

All participants were administered the dream questionnaire developed by Solms (1997). This questionnaire comprised of a series of questions regarding specific aspects of their dreams; including the narrative complexity of their dreams, the effect of their illness on their dreaming experience, general duration and emotional intensity of dreams, and so forth.

Polysomnographic measures

The PSG recordings were completed on a portable Alice © 5 *Respironics* polygraphic amplifier (Cape Sleep Centre, Gatesville Medical Centre, Cape Town). The American Association of Sleep Medicine (AASM) recommended recording montage was used in this study. This included: electroencephalogram (EEG; 4 leads, 2 channels); electrooculogram (EOG; 2 channels); the submental electromyogram (EMG; chin and leg). It also included chest and abdominal strain gauges, snore microphone, positional marking and finger pulse

oximetry. Sleep stages were visually scored for 30-s epochs by a certified polysomnographic technologist based on AASM standard criteria (Hirshkowitz & Sharafkhaneh, 2009).

Neuropsychological Tests

The neuropsychological tests that were used in this study focus on higher visual and spatial perception, visual and audio-verbal long term memory and visual and verbal short term memory. Assessing these functions prevents potential confounding of the results seen with cessation of dream experience by memory dysfunction. The neuropsychological tests chosen, along with their associated scoring methods, are currently being used on a daily basis in neuropsychological assessments in Groote Schuur Hospital, and are standard measures that are internationally validated (Strauss, Sherman & Spreen, 2006).

Visuo-spatial perception.

Visuo-spatial perception was assessed using subtests from Luria's Neuropsychological Investigation. These subtests assess higher visual perception and intergration, and included (i) Object recognition (ii) Visual recognition of letters, words and phrases (iii) Calculations (iv) colours (v) language (Christensen, 1974). The Boston Naming Test was also used (Kaplan, Goodglass & Weintraub, 2001).

Constructional praxis.

Perceptual organization and constructional praxis were tested using the WAIS-III Blocks (The Psychological Corporation, 1997). The Rey-Osterrieth Complex Figure was also administered (ROCF; Rey, 1941; Osterrieth, 1944).

Short-term memory.

The Digit Span Test was used to assess audio-verbal short-term memory, while visual short-term memory was tested using Corsi's Blocks (WMS-III; Wechsler, 1997).

Visual and verbal memory.

Long term verbal memory was assessed using the Babcock Story (Babcock & Levy, 1930). Short-term and long term visual memory was further assessed using the ROCF. The ROCF administration comprises a copy trial, an immediate recall trial, and a delayed recall trial (after approximately 30 minutes). Long-term visual memory was further assessed by Benton's Visual Retention (Sivan, 1992). In addition, The Bicycle Drawing Test (BDT), the South African flag, a canary, a house, and the revisualisation of the sleep laboratory, were all included for the purpose of assessing the patients' ability to revisualise images from memory (Lezak, 1995).

Design

A multi-case clinicoanatomical study was used to examine the neurological correlates of global cessation of dreaming. The dependent variable measured in this study is cessation of dreaming, while the independent variable is occipito-temporal damage. For the purpose of this study, cessation of dreaming refers to the absence of any sensory imagery (visual, auditory, or kinaesthetic) during REM sleep.

The two groups comprised neurological patients with unilateral or bilateral, thrombotic infarctions in the occipito-temporal region. The MRI and neurological data was analysed in relation to each other, and previous relevant case reports. All patients were required to spend one night in the sleep lab during which they were subjected to semi-spontaneous REM sleep interviewing. This interview was used to verify the experimental and control groups.

Considering the clinical evidence that dream loss is associated with damage to the occipito-temporal region, this study focused specifically on subjects with injuries to this region. Subjects with non-haemorrhagic posterior cerebral artery (thrombotic) strokes, which resulted in the according cerebrovascular insults, were studied. Non-haemorrhagic infarctions are ideal specimens for clinicoanatomical study, as they result in focal, circumscribed damage which allows for more accurate correlation between the lesion and resulting clinical presentation (Damasio & Damasio, 1989).

All participants suffered PCA stroke that resulted in either bilateral or unilateral damage to the occipito-temporal region. The precise functional anatomy of their brain regions were established through the strict coding criteria adopted by magnetic resonance imaging (MRI) standards. The exact locations of the brain lesions were strictly charted and coded in accordance with Brodmann's system (Brodmann, 1909; Damasio & Damasio, 1989). A compilation of neuropsychological tests was used in order to exclude any confounding neurocognitive deficits that might affect dream recall; namely verbal memory and visual memory.

Data analysis

This study adopted a clinicoanatomical approach in the analysis of data. Each participant was analysed as a case study in comparison to matched controls. The MRI and CT scans, in combination with the neurology reports, were analysed to determine the precise

location, laterality and acuteness of the lesions. These were then related to respective dreaming experience.

A descriptive analysis was written for the presenting cases in comparison with Wilbrand's (1887) cases, Bischoff and Bassetti's case (2004) as well as Yu's (2001) meta-analysis. In addition, a between-groups descriptive analysis will also be performed between the experimental and control group.

Neuropsychological Tests. The neuropsychological tests were analysed by way of the *hypothetical-deductive approach*, as used by the neuropsychologists at Groote Schuur Hospital in their everyday clinical practice. Specifically, the test scores whether analysed in order to determine whether any alterations in dreaming experience could be conflated by neuropsychological functioning. Scoring of the neuropsychological tests was done according to the standard procedures outlined with each test.

Procedure

The participants were selected from referrals by neurologists at Groote Schuur Hospital and Gatesville Medical Centre, as part of a larger ongoing dream study currently being undertaken at UCT, and then given to the author. Permission from both the attending physicians, and consent from each participant, was obtained before any data was collected, again as part of the larger masters study. Moreover, the participants were screened using various neuropsychological tests (see below) to ensure they were cognitively able to participate.

This study comprised of three primary components (i) assessment of dream experience (ii) neuropsychological assessment and (iii) analysis of brain lesions. The neuropsychological testing took place at Groote Schuur Hospital, where a quiet room was used. The sleep study was completed at the Cape Sleep Centre at Gatesville Medical Centre — an approved AASM sleep Laboratory — where the PSG recording was professionally monitored by a qualified sleep technologist. MRI and CT scans, as well as neurology reports from the participants' medical examinations, were all used to determine lesion site and dreaming experience. An identical procedure was applied to both group (a) and group (c).

All participants were administered the dream questionnaire developed by Solms (1997) and provisionally assigned to groups heteromodal loss, unimodal loss or preservation on this basis. This questionnaire comprised of a series of questions regarding specific aspects

of their dreams; including the narrative complexity of their dreams, the effect of their illness on their dreaming experience, general duration and emotional intensity of dreams, and so forth. The assignment to these groups was then confirmed on the basis of awakening on first night in the Gatesville Medical Centre sleep lab, and morning recall questionnaires administered on the following morning and on the morning after a second night in the sleep lab in which they were not awakened (see below).

Sleep Study: REM awakenings

In order to confirm participants' reports of their dreaming experience, they all underwent an experimental night in the Gatesville Medical Centre sleep laboratory. Each participant was informed of the procedures and main purpose of the study, and a consent form was signed prior to data collection. Furthermore, each participant was informed of his/her freedom to withdraw from the study at any point without consequence, if s/he so wish.

During this experimental night, two REM awakenings were made. The participants were connected to a polysomnograph and simply asked to sleep as they normally would at home. The participants were awakened during the second and third REM sleep periods by the researcher in order to confirm whether or not they were dreaming. The participants were awakened in accordance with the specific physiological variables of REM present in the EEG recordings. The interview consisted of briefly asking participants, during unprompted REM awakening, if they were dreaming and what was going through their mind prior to being awoken.

Polysomnographic recordings were professionally monitored by a qualified sleep technologist. For the experimental group, the REM sleep interviews would confirm that they were not dreaming. For the control group, these would confirm that they were dreaming. On the basis of the participants' subjective reports *and* this confirmation of dreaming experience, the six participants were subsequently divided into the experimental and control group.

Differentiation of loss of dreaming from forgetting of dreaming was further confirmed by obtaining verbal reports on the second morning of what had happened during the two preceding nights, from arrival at the sleep lab until falling asleep and during the lab awakenings and in the morning before departing the sleep lab. The participants were required to describe to the researcher, the sleep laboratory, and the process and awakenings in great detail, in order to exclude visual or verbal deficits as potentially confounding variables in dream recall.

Neuropsychological testing

Neuropsychological testing was also conducted on visual memory: The Luria's Neuropsychological Investigation (LNI) was used to assess higher visual perception and integration. In addition, the Spatial span, Boston Naming Test (BNT) and Visual Imagery test were used to assess short-term visual memory. Long term memory was assessed using Benton's Visual Retention Test (BVRT) and the Babcock Story. Similar tests were conducted on verbal memory: The digit span tested audio-verbal short-term memory. Visuo-spatial tests were also used: The WAIS-III blocks was chosen to assess perceptual organisation and constructional praxis, and the Rey-Osterrieth Complex Figure was used to assess visual-spatial construction ability (see Appendix XX).

MRI and CT Scans

After participant consent was gained, all MRI scans of all cases were obtained from the existing clinical records (scan taken after CVA on date closest to that of the dream and neuropsychological investigations). A specialist radiologist then coded the scans by Brodmann's areas, in accordance with the atlas of Damasio & Damasio (1989). The lesions sites in the two groups were then compared.

Ethical Considerations

All participants were required to sign consent forms before any data was collected. Participants were also provided monetary compensation for their participation in this study. The study adhered to both the ethical guidelines for research with human subjects as specified by the Health Profession Council of South Africa (HPCSA), and the University of Cape Town (UCT) Codes for Research. Ethical approval was obtained from the Psychology Department's Research Ethics Committee at UCT, as well the Faculty of Health Sciences Research Ethics Committee at UCT.

Results

In total, five cases that met both the inclusion and exclusion criteria for this study were available for investigation. Two of these patients (Case 1 and 2) reported heteromodal (global) loss of dreaming, while none of the patients reported unimodal loss. Four of the patients (Cases 3, 4, and 5) reported that their dreaming was preserved. The correct classification of the patients to these groups was confirmed in the sleep lab through the awakenings on the first night, along with the morning recall questionnaires administered on

the following morning and on the morning after a second night in the sleep lab, in which the patients were not awakened.

Case 1: Mrs A

Date of birth: 10/ 03/ 1951

Date of CVA: 25/ 02/ 2006

Date of dream assessment: 25/ 08/ 2010

Code age and number of weeks post CVA: 59 years; 232 weeks

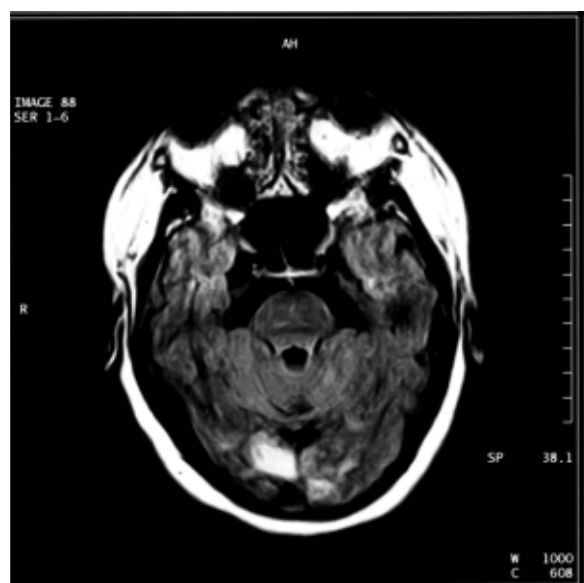Pathology: Bilateral thrombotic infarction in the PCA territory

Code dream status: Group (a)

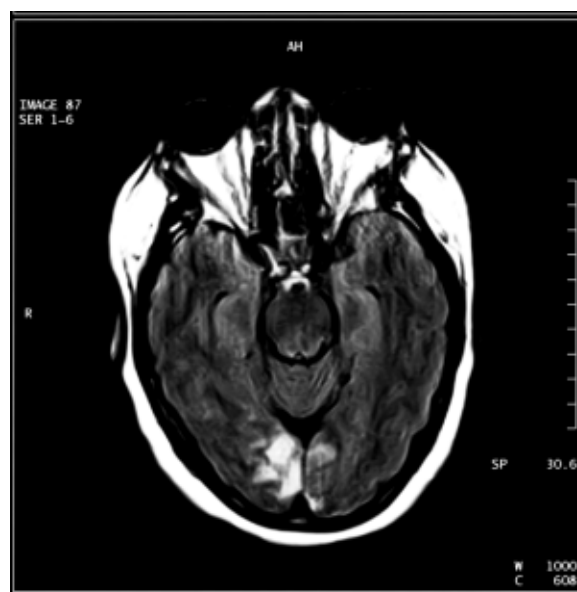Dream recall: Mrs A was interviewed twice during separate unprompted REM awakenings to ask if he had been dreaming. The awakenings were semi-spontaneous and were performed during the second and third REM sleep cycle. Mrs A reported that she had not been dreaming, or experiencing any other thoughts or mentations, prior to both REM awakenings.

Scan showing pathology: Mrs A

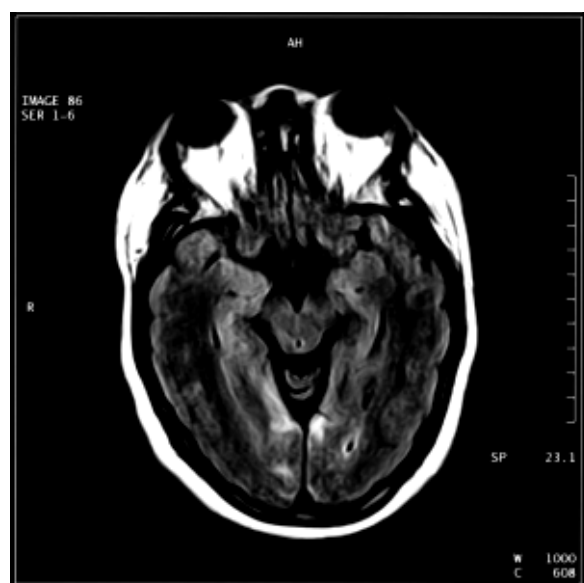
A



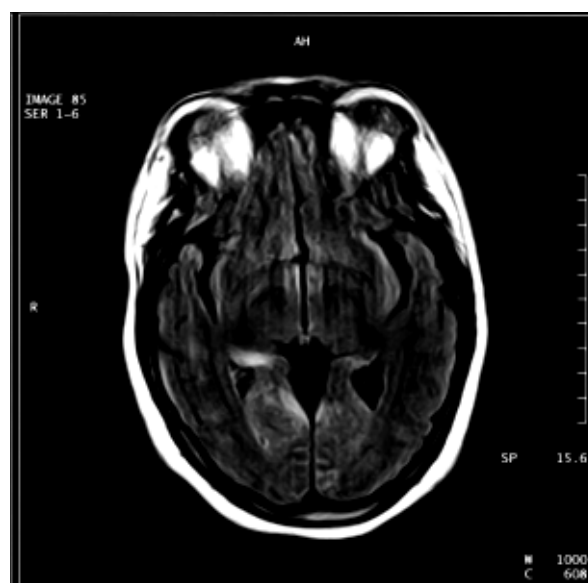B



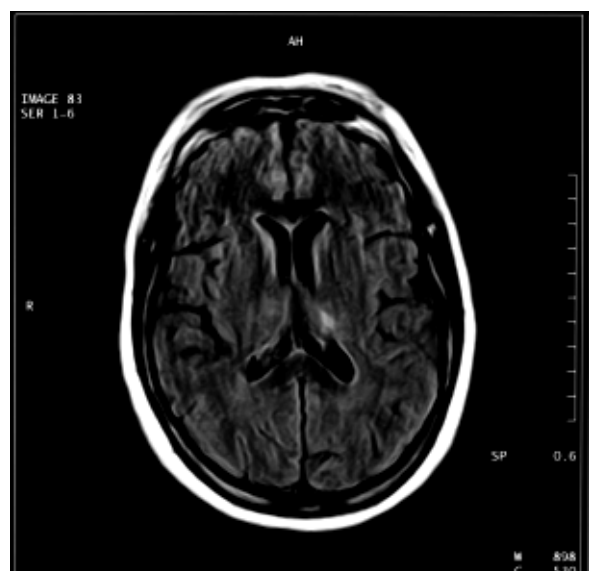
C



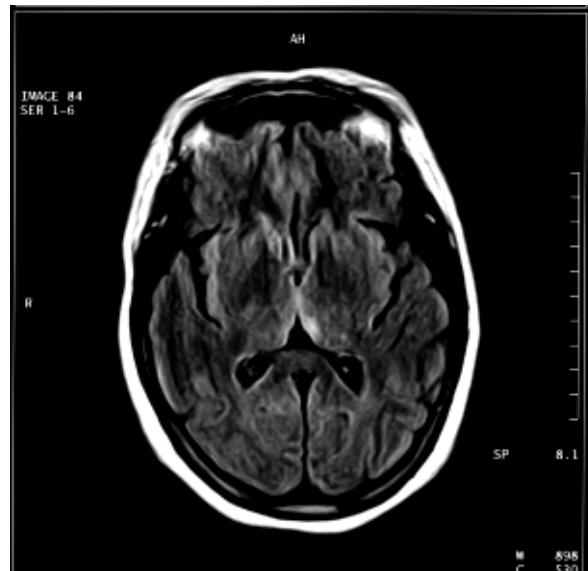
D



E



F



Summary of the findings from the neuropsychological testing:

Testing of Mrs A's long term memory showed that she did not display any major verbal or visual memory deficits. Mrs A had normal visuo-spatial perception. Mrs A's ROCF was poor. Her performance in LNI showed that she successfully recalled all visual images. Her performance in both Corsi's blocks and the Digit span test were normal. Likewise, the Visual Imagery test showed that her visual short term memory was intact. Her BNT results confirmed that she was not aphasic and confirmed that her lack of dream recall was not due to verbal communication deficits.

Case 2: Mrs C

Date of birth: 1949/01/10

Date of CVA: 2011/02/07

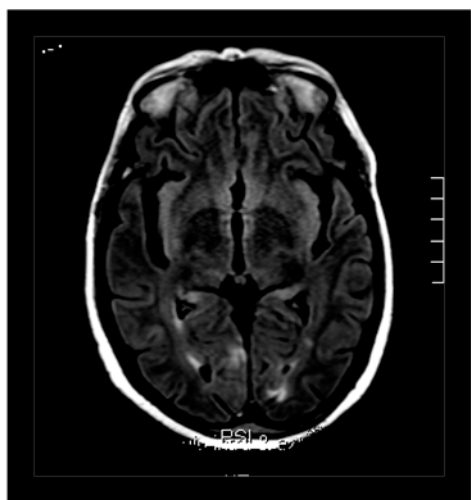
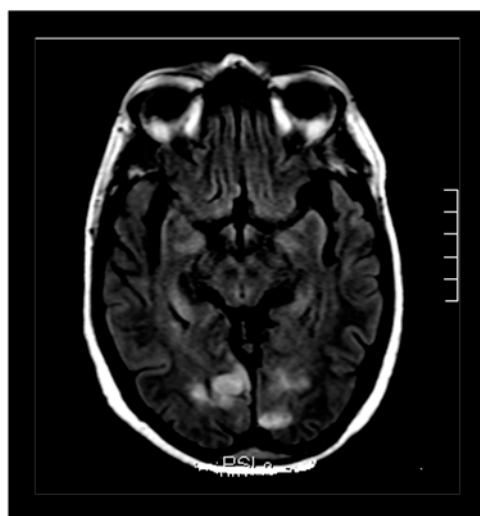
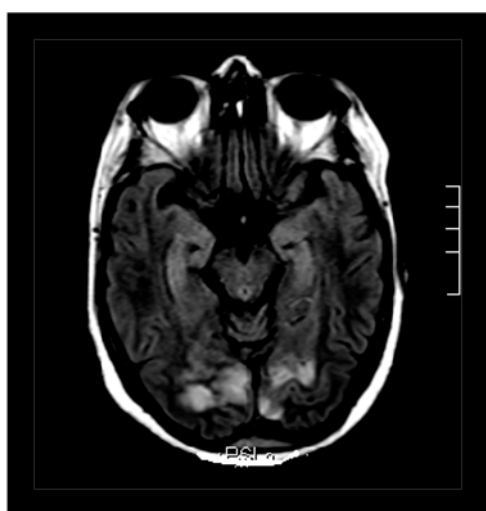
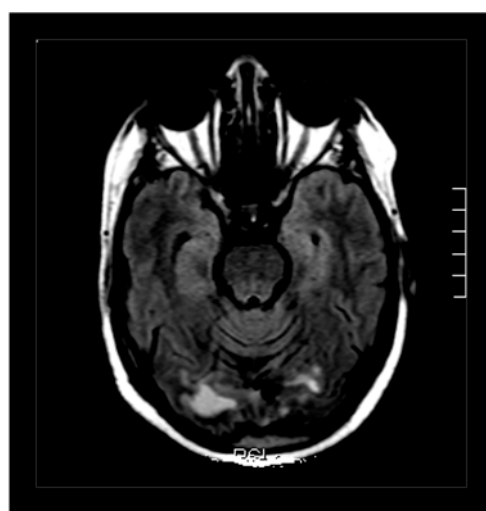
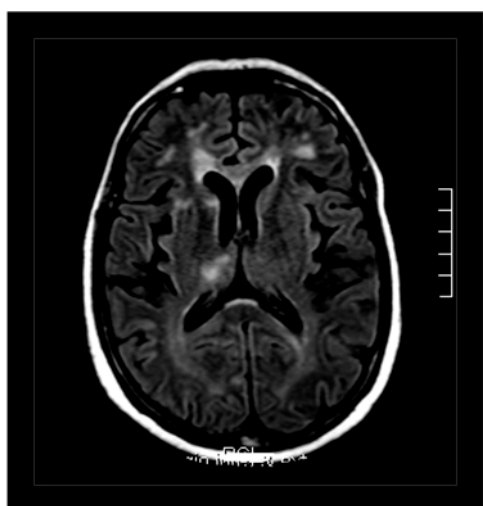
Date of dream assessment: 2011/07/12

Code age and number of weeks post CVA: 62 years; 22 weeks

Pathology: Bilateral thrombotic infarction in the PCA territory.

Code dream status: Group (a)

Dream recall: Mrs C was interviewed once during separate unprompted REM awakenings to ask if she had been dreaming. Two awakenings were not done as Mrs C had only entered REM sleep once during the experimental night. Upon awakening, she confirmed that she had not been dreaming. However, a third sleep study night was booked specifically to confirm whether Mrs C was indeed a non-dreamer, the two awakenings from this night, as well as her subjective account verified that she was, in fact, a non-dreamer. The awakenings were semi-spontaneous and were performed during the second and third REM sleep cycle. Mrs A reported that she had not been dreaming, or experiencing any other thoughts or mentations, prior to both REM awakenings.

Scan showing pathology: Mrs C**A****B****C****D****E**

Summary of the findings from the neuropsychological testing. Neuropsychological testing showed that Mrs C did not present any verbal or visual memory deficits. However, Mrs C presented with mild apperceptive visual agnosia. Nonetheless, her performance in the ROCF test showed no visual long-term memory deficits. Corsi's Blocks and the Visual Imaging test indicated that she had intact visual short-term memory. In addition, Mrs C was able to accurately recount visuo-spatial details of the sleep-study nights; indicating intact visual episodic memory. The digit span test confirmed her intact audio-verbal short-term memory, and the BNT verified that she was not anomic.

Case 3: Mr R

Date of birth: 1960/05/09

Date of CVA: 2010/12/23

Date of dream assessment: 2011/06/27

Code age and number of weeks post CVA: 51 years; 29 weeks

Pathology: Thrombotic infarction in the PCA territory.

Code dream status: Group (c) Preserved

Dream recall

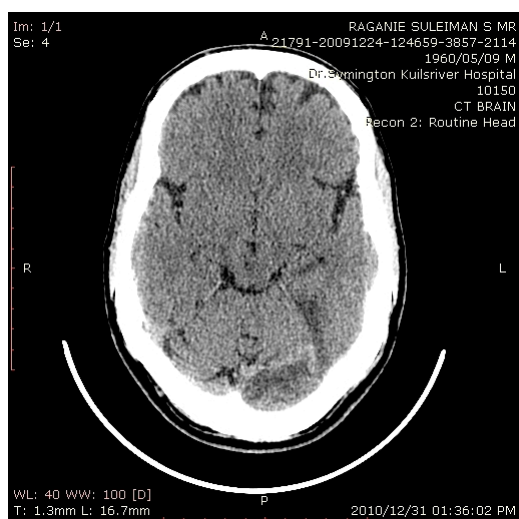
Mr R was interviewed twice during separate unprompted REM awakenings to ask if he had been dreaming. The awakenings were semi-spontaneous and were performed during the second and third REM sleep cycle. Mr R reported that he had indeed been dreaming prior to both REM awakenings.

Summary of the findings from the neuropsychological testing:

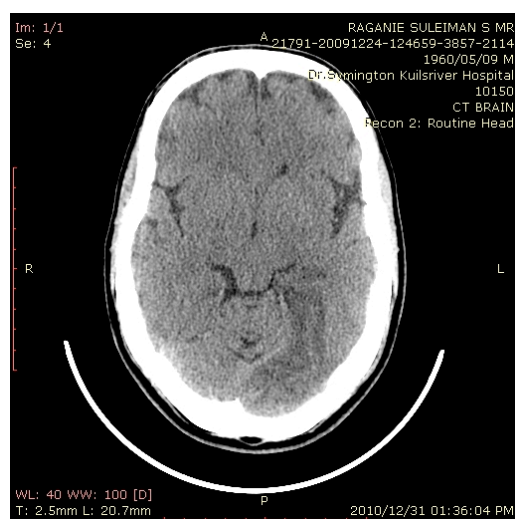
Testing of Mr R's long term memory showed that he did not display any major verbal or visual memory deficits. Mr R had normal visuo-spatial perception. Mr R's immediate recall on the ROCF was poor. His performance on the Digit span as well as the BVRT was also poor. Likewise, the Visual Imagery test showed that her visual short term memory was intact. The BNT results confirmed that he was not aphasic and confirmed that his lack of dream recall was not due to verbal communication deficits.

CT scan showing pathology: Mr R

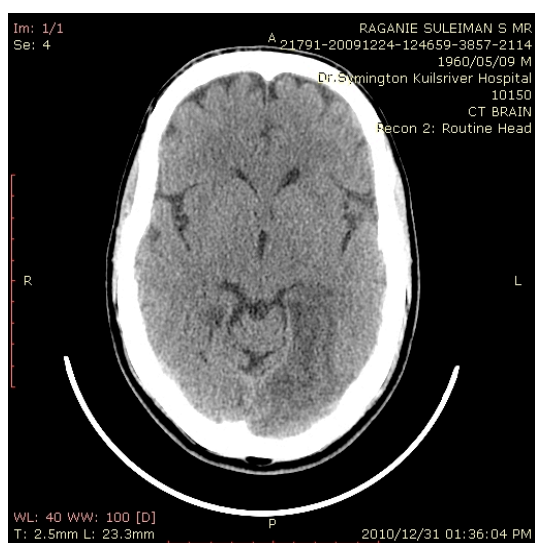
A



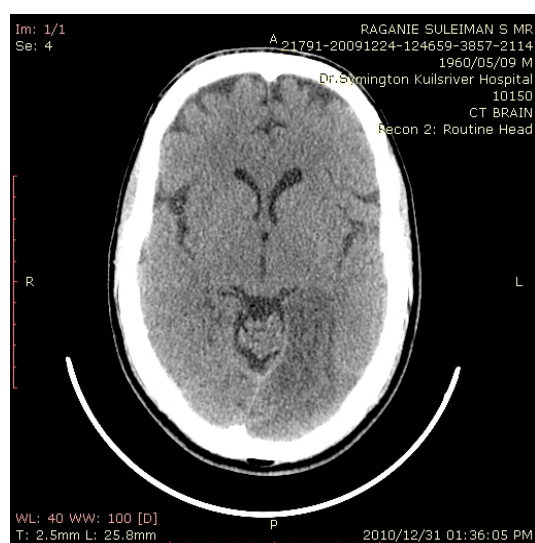
B



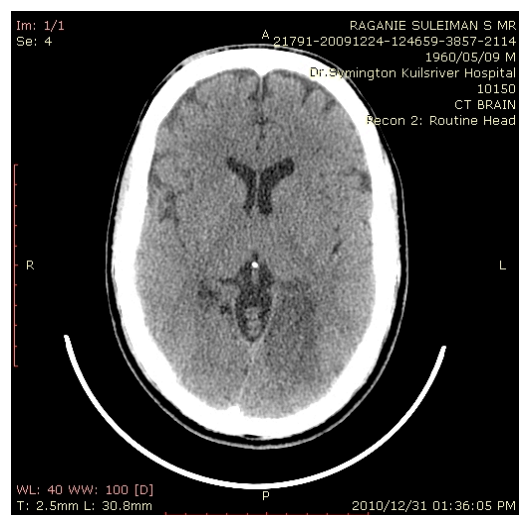
C



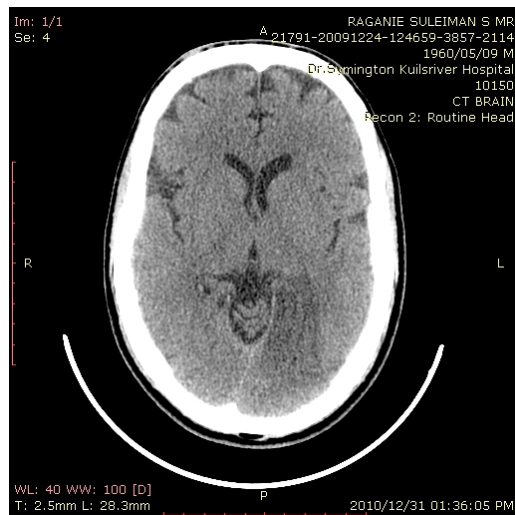
D



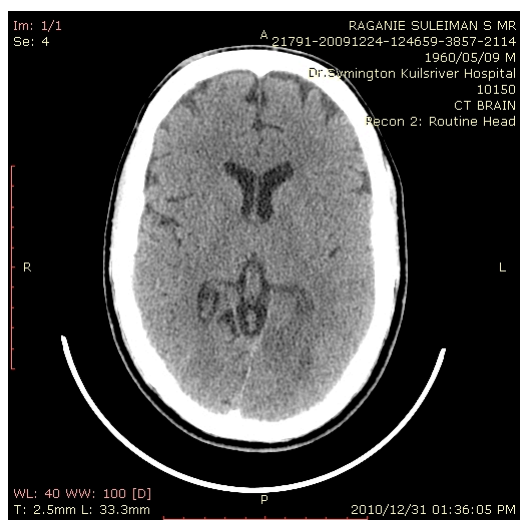
E



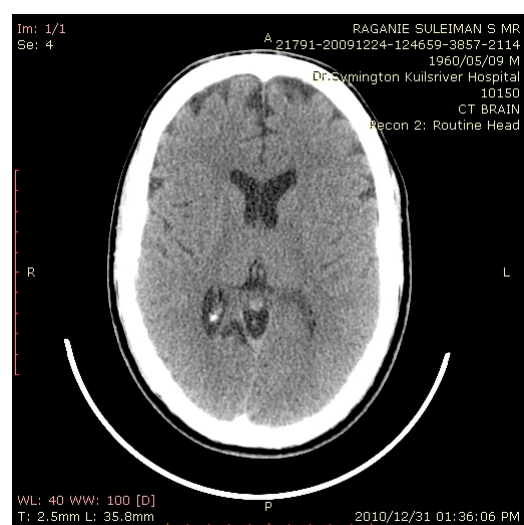
F



G



H



Case 4: Mr B

Date of birth: 1943/08/30

Date of CVA: 2010/02/11

Date of dream assessment: 2011/04/18

Code age and number of weeks post CVA: 67 years; nine weeks

Pathology: Acute right thrombotic infarction of the PCA territory

Scan showing pathology:

Code dream status: Group (c) Preserved

Dream Recall:

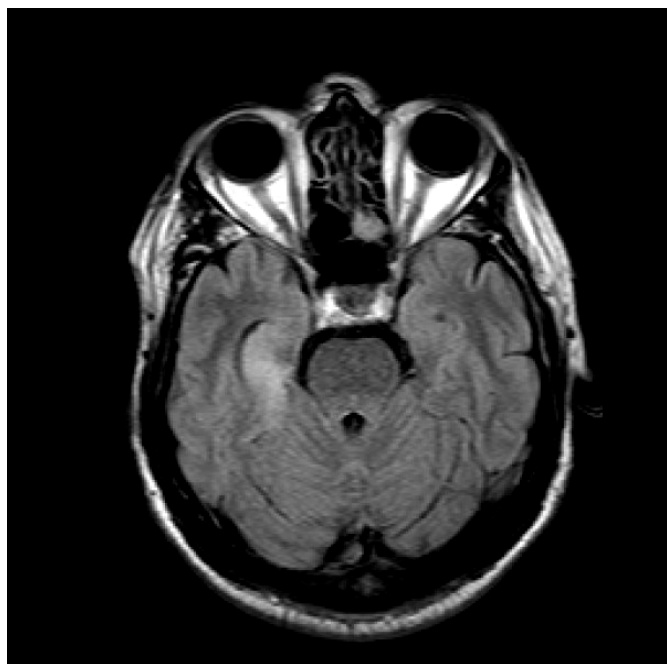Mr. B was interviewed twice during separate unprompted REM awakenings to ask if he had been dreaming. The awakenings were semi-spontaneous and were performed during the second and third REM sleep cycle. Mrs R reported that he had been dreaming prior to both REM awakenings.

Summary of neuropsychological testing:

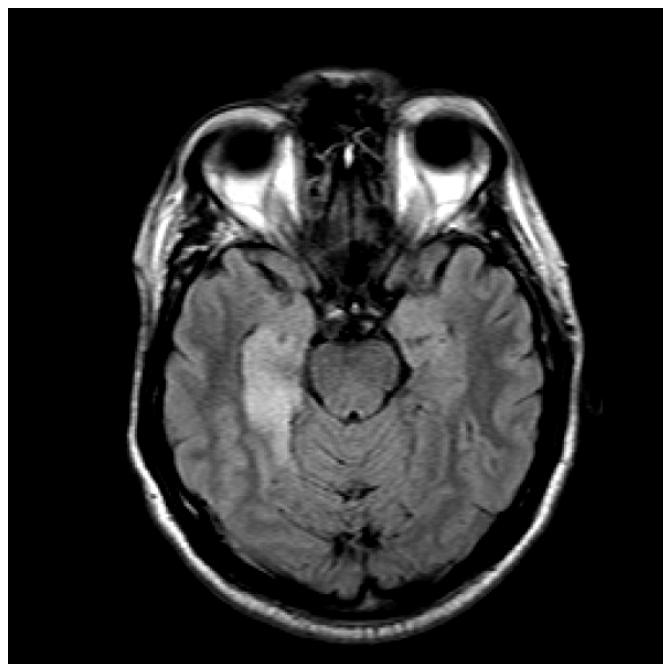
Mr B demonstrated intact function in both the verbal and visual memory spheres. His immediate recall score in the ROCFL was relatively low performed satisfactorily in both the Digit span test as well as Corsi's Blocks. He performed well on both Babcock's test of verbal memory, and the Visual Imagery test. LNI was normal. There were no outstanding deficits present in Mr B's scoring.

MRI scan showing pathology: Mr B

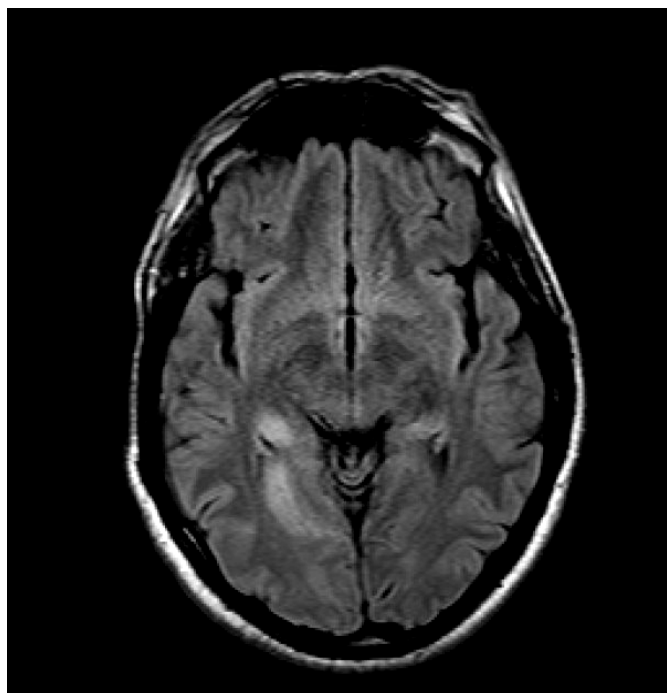
A



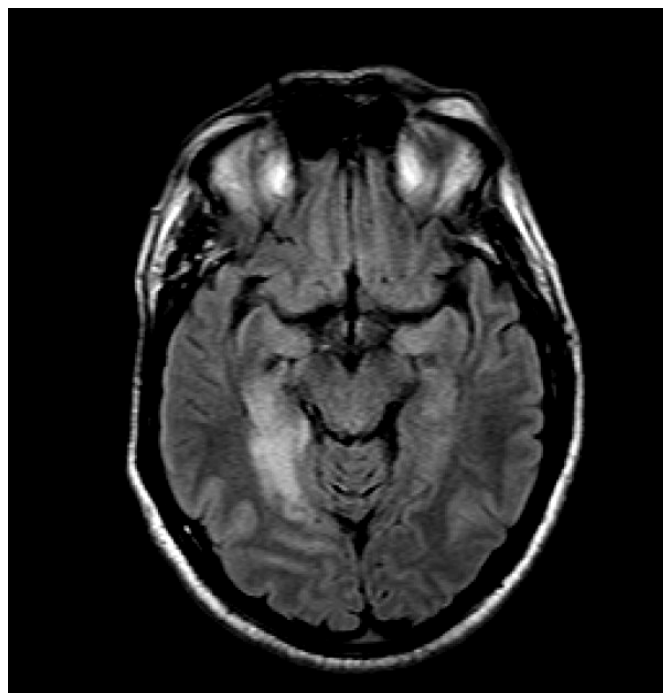
B



C



D



Case 5: Mrs J

Date of birth: 1965/09/12

Date of CVA: 2007/03/27

Date of dream assessment: 2011/07/20

Code age and number of weeks post CVA: 45 years; 224 weeks

Pathology: Thrombotic infarction of the PCA territory

Dream recall

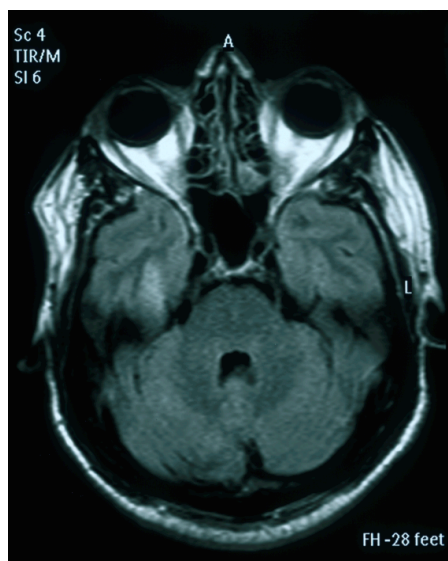Mrs. J was interviewed thrice during separate unprompted REM awakenings to ask if he had been dreaming. The awakenings were semi-spontaneous and were performed during the first, second and third REM sleep cycle. During the first REM-awakening interview, Mrs. J reported having thoughts. Mrs. J reported that she had been dreaming prior to the second REM awakening, but stated that she could not remember her dream from the third awakening.

Summary of the findings from the neuropsychological testing:

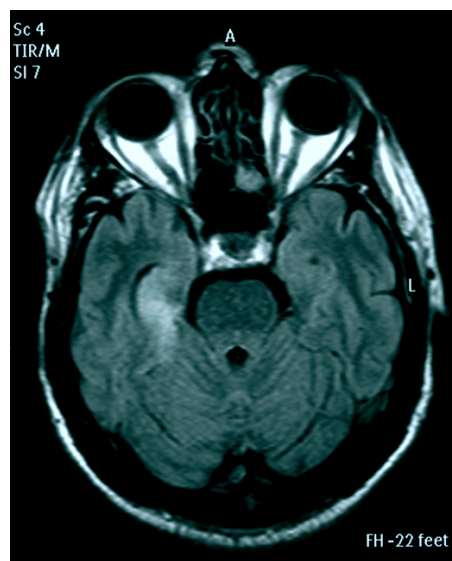
Mrs J's scores did not reveal any outstanding deficits that could affect dream recall. LNI was normal. However, her performance in the BVT was poor, showing reduced long term memory. Her Digit span score and ROCF score (for immediate recall) was also poor. Nonetheless, she demonstrated the intact ability to revisualise events objects from memory, according to the Visual Imagery test. She also demonstrated intact verbal memory, according to the Babcock story. Overall, neuropsychological testing of Mrs J showed that she did not suffer from any serious visual or verbal memory deficits

Scan showing pathology: Mrs J

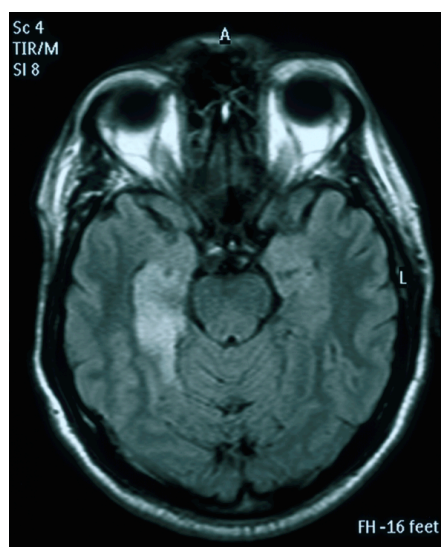
A



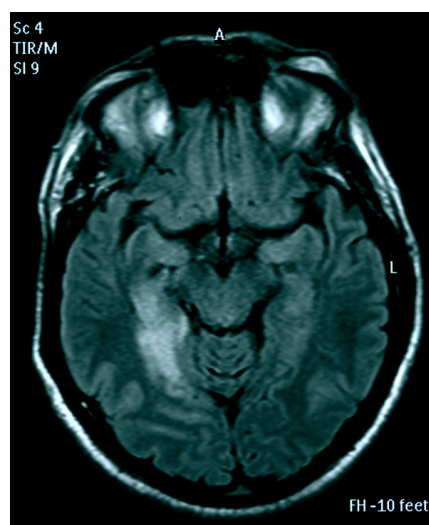
B



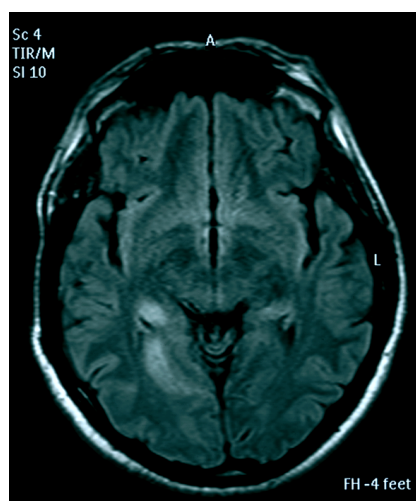
C



D



E



Composite tables of Brodmann's Areas

Table 4. Group (b) Preserved Dreaming

Participant	Weeks post-CVA	Left	Right
Mr. R	29	BA17	
		BA18	
		BA19	
		BA20	
		BA28	
		BA31	
		BA36	
		BA37	
Mr. B	9		BA28
			BA36
			BA37
Mrs. J	224		BA28
			BA36
			BA37

Table 3. Group (a) Global cessation of dreaming

Participant	Weeks post-CVA	Left	Right
Mrs. A	232	BA19	
		Thalamus	
		BA37	BA37
		BA18	BA18
Mrs. C	22		BA37
			BA36
			Thalamus
		BA19	BA19
		BA18	BA18

Table 5. Composite table of neuropsychological test means

Neuropsychological Testing	Overall (N=5)	<u>Mean</u>	
		Non- dreaming (N=2)	Preserve d dreaming (N=3)
Boston Naming Test	42.8	51	36.6
Rey-Osterrieth Complex Figure			
Copy	30.2	37	29
Immediate Recall	8.2	9.5	7.3
WAIS-III Blocks	22.4	26.5	19.6
Corsi's Blocks			
Forward	6	7	8
Backward	4.6	5.5	4
Digit Span Test			
Forward	5	5.5	7
Backward	3.6	5.5	5.5
Benton's Visual Retention Test	4.25	6	2.5

Discussion

This study attempted to confirm a recent case report by Bischoff and Bassetti (2004) that heteromodal (global) loss of dreaming can occur with Posterior Cerebral Artery (PCA) lesions, particularly those confined to the medial occipito-temporal region — a lesion site that had previously been associated with unimodal (visual) loss of dreaming. The precise localization of the lesion responsible for this global loss of dreaming was studied in order to assess whether heteromodal and unimodal dream loss can be differentiated from each other, and from preserved dreaming, in terms of lesion site.

In line with the classical case of Wilbrand (1887), as well as Bischoff and Bassetti's (2004) case, this study has confirmed its first hypothesis that global cessation of dreaming does indeed occur with pure medial occipito-temporal lesions. Specifically, cessation of dreaming has been verified in two patients: Mrs A (Case 1) and Mrs C (Case 2). Polysomnographical recordings showed that both these participants experienced REM sleep on both nights in the sleep laboratory, while the REM-awakenings confirmed that both did indeed have complete dream loss. Neuropsychological testing confirmed that both these patients displayed none of the relevant neurocognitive deficits that could have undermined their ability to recall their dreams. The neuropsychological assessments revealed that both Mrs A and Mrs C did not display short term or long term memory deficits in either the verbal or visual sphere, in comparison with patients in whom dreaming was preserved.

Testing of Mrs A's long term memory showed that she did not display any major verbal or visual memory deficits. Mrs A had normal visuo-spatial perception, and no prosopagnosia or agnosia. Mrs A's ROCF performance was affected by primary visual difficulties, such as blurred vision and photophobia, which prevented her from successfully completing the test. Nonetheless, her performance in LNI would compensate for this fact, as she successfully recalled all visual images. Her performance in both Corsi's blocks and the Digit span test also indicated that she has intact short-term visual and verbal memory. Likewise, the Visual Imagery test showed that her visual short term memory was intact. In addition, Mrs A was able to accurately recount visuo-spatial details of the sleep-study nights; indicating intact visual episodic memory. Furthermore, Mrs A was able to subsequently recall accurate visual-spatial detail of the sleep-study nights, which indicated no deficits in overall visual episodic memory. Her BNT results confirmed that she was not aphasic and confirmed that her lack of dream recall was not due to verbal communication deficits.

Mrs C presented with mild apperceptive visual agnosia. However, her performance in the ROCF test showed no visual long-term memory deficits. This was supported by her performance on Corsi's Blocks and the Visual Imaging test, which indicated that she had intact visual short-term memory. In addition, Mrs C was able to accurately recount visuo-spatial details of the sleep-study nights; indicating intact visual episodic memory. The digit span test confirmed her intact audio-verbal short-term memory, and the BNT verified that she was not anomie.

At first glance, these findings, together with the case reports of Wilbrand (1887, 1889) and Bischoff and Bassetti (2004), seem to contradict Solms' (1997) attribution of global cessation of dreaming to a lesion in the lateral (heteromodal) association cortex and non-visual dreaming to a lesion in the medial (unimodal) association cortex. However, on inspection, all three patients with reported total loss of dreaming—the two cases presented in this study and Bischoff and Bassetti's case—all had lacunar lesions to the posterolateral thalamus in addition to their medial occipito-temporal lesions. Specifically, a lesion the right posterolateral aspects of the thalamus in Mrs C's case, and the postero-medial-lateral aspects in Mrs A's case. In the case of Bischoff and Bassetti, the thalamic lesion is in the right posterolateral aspect of the thalamus; identical to Mrs C's case. Crucially, the posterolateral thalamus projects to lateral (heteromodal) association cortex (Walsh & Darby, 1999). Therefore, the possibility of the thalamus being responsible for the global loss of dreaming in such cases cannot be excluded given its heterogeneous projections to heteromodal cortex. It is unclear whether the thalamus in Wilbrand's case was inspected at autopsy, as his case was reported years before the development of in vivo imaging. At this stage, the role of the thalamus in the generation of dreaming is still uncertain. In the light of this key observation, the role of the thalamic lesions and the affect on heteromodal cortex in such cases of reported total dream loss requires further research and investigation in the future.

In light of the above cases, it also remains unclear as to whether the presence of bilateral lesions may be responsible for the total loss of dreaming in patients predicted, according to Solms, to only have visual loss of dreams. For example, Solms (1997) case of Charcot-type dreaming loss (i.e. visual loss of dreaming was a *unilateral* right medial occipito-temporal tumour in the fusiform gyrus (BA36 and 37).

Three of the five PCA territory stroke cases in this study did have intact dreaming (Case 3, 4, and 5). The second hypothesis of this study can be addressed in the light of these three cases in relation to the two non-dreamers. This second hypothesis was to establish

whether differences in lesion site could be identified between heteromodal versus unimodal dream loss. Here, this could only be addressed in relation to the lesion site in total dream loss cases and preserved dreaming cases, as no unimodal dream loss cases were identified in this study.

The precise localisation of the lesions was closely examined. The dreaming versus non-dreaming cases were compared in terms of damaged Brodmann's areas. Damaged Brodmann's areas in both non-dreaming participants (Mrs A and Mrs C) converged on bilateral damage to BA18 and 19. Mrs A also had bilateral damage to BA17 and 37, while Mrs C had right hemisphere damage to BA36 and 37. Both participants had unilateral lacunar infarcts in the posterolateral thalamus. Interestingly, type (c) participants (Mr R, Mr B and Mrs J) presented with different sites of damage. Mr B and Mrs J both had damage to BA28, 36, and 37 in the right hemisphere. Mr R presented with the largest area of lesion damage which encompassed all the areas noted in both non-dreamers, making his an intermediate case. Specifically, Mr R presented with damaged areas consistent with the non-dreamers — BA17, 18, 19, and 37 — as well as damage to additional anterior areas BA20, 28 and 31. Regardless of the similarity in the Brodmann's areas of both the dreaming and non-dreaming group, it is significant that the damaged areas in non-dreaming patients were always unilateral, while non-dreaming patients were unilateral.

Three key observations have been made on the basis of the findings regarding differences between the non-dreaming cases, and the dreaming cases. Firstly, all three dreamers in this study had unilateral lesions, whereas the two non-dreamers both had bilateral lesions (as did Bischoff and Bassetti's case, and Wilbrand's case).

Secondly, as mentioned above in relation to the Bischoff and Bassetti case, both non-dreamers also had lesions to the posterolateral thalamus, whereas none of the three dreaming patients in this study had thalamic involvement.

Thirdly, inspection of the MRI scans of the three dreaming cases revealed that all three had lesions with more temporal lobe and parahippocampal involvement relative to occipital-temporal involvement. Here, Mr R, who had both occipital and temporal damage, can be considered to be an intermediate case, whereas Mr B and Mrs J had lesions that were more anterior and temporal. This is in contrast to the two non-dreamers whose lesions were more posterior, toward the occipital lobe. This is consistent with the lesion area in both Wilbrand's and Bischoff and Bassetti's case reports.

Another interesting finding is that the neuropsychological evidence from the testing done in this study is consistent with the more anterior lesions of the three dreaming patients. Specifically, these patients all had poorer memory performance relative to the non-dreamers, which is consistent with lesions of the temporal lobe and parahippocampal area.

Given the three key differences identified between the dreamers and the non-dreamers, it may be the case that damage to the unimodal occipito-temporal cortex requires bilateral damage in order to result global cessation of dreaming – as in the case of Mrs A and Mrs C, as well as Wilbrand's and Bischoff and Bassetti's cases – while damage to the lateral heteromodal cortices need only be unilateral to have the same effect. In support of this, Solms (1997) reports a case with a unilateral right medial occipito-temporal tumour in the fusiform gyrus (BA36 and 37). This patient suffered from poor visual acuity and photophobia. Logically, heteromodal (global) areas are involved in more higher-order integration, thus minimal damage may result in the loss of a wider range of perceptual processes. The converse would apply in the event of damage to the medial (unimodal) regions. Until further cases are observed, this theory cannot be proved, and remains simply a speculative explanation. Further research, comparing unilateral and bilateral damage of both the medial and lateral regions, would shed light on this potential hypothesis. Again, the contribution of thalamic lesions in relation to dream loss also needs to be further investigated.

In addition, acuteness of the lesions was also considered in this study on the basis that Solms (1997) observed that loss of dreaming typically recovers after the acute period. This is consistent with Wilbrand's case who reported seeing the image of her late sister in a dream 10 years after her CVA. Similarly, Mrs A (Case 1) reported having had a dream for the first time, four years and 7 months, after her CVA. Nonetheless, the findings in this study cannot attribute dream loss with acuteness of stroke based on the fact that there is no difference in the mean number of weeks post CVA between the two groups. Furthermore, all the dreaming cases in reported preservation of dreaming in the acute period, and were therefore not recovered total loss of dreaming cases. In fact, two of the dreaming cases, Mr R and Mr B, were in the relatively acute period during testing (29 weeks and nine weeks respectively) and confirmed preservation of dreaming. However, based on the small sample size with largely varying acuteness, it is impossible to conclusively determine the significance of acuteness in the recovery of dreaming in patients with type (a) dream loss. Future research should focus on longitudinal studies that address this specific variable.

In conclusion, Mrs. A and Mrs C are the third and fourth comprehensively documented cases of total loss of dreaming as a result of bilateral medial-occipito-temporal lesions. Thus, the hypothesis that global cessation of dreaming occurs with pure medial occipito-temporal lesions has been confirmed. In particular, the two dream loss cases are strikingly similar to Bischoff and Bassetti's (2004) case and Wilbrand's original case. However, given that posterolateral thalamic lacunar lesions are present in three of these cases (Wilbrand's is not known), definite conclusions about original definition of Charcot-Wilbrand Syndrome, and the reformulation of this syndrome by both Solms' (1997) and Yu's (2001), cannot yet be reached until such time as a number of further studies have been undertaken.

The second hypothesis, that lesion sites would differ from cases in medial occipito-temporal lesions or in which global loss of dreaming occurs, was investigated using MRI scans, in conjunction with comparative analyses. The results revealed three key differences between the non-dreamers and dreamers. Firstly, lacunar infarction to the thalamus was observed in the non-dreamers only. Secondly, the lesions in the non-dreamers were bilateral, as opposed to unilateral lesions in the dreaming cases. Finally, the non-dreamers presented with lesions toward the occipital lobe (more posterior), while the dreamers presented with more anterior lesions toward the temporal lobe.

Thus, this study has supported the hypothesis that lesion sites will be different between cases with medial-occipito-temporal lesions in which dreaming is preserved or global loss of dreaming occurs. This study made use of various cases and previous literature to provide a heuristic explanation, which will hopefully lead to further scientific research in the field of dream science.

References

- American Psychiatric Association. (2005). *Publication manual* (5th ed.). Washington, DC: American Psychiatric Association.
- Aserinsky, E., & Kleitman, N. (1953). Regularly occurring periods of eye motility, and concomitant phenomena, during sleep. *Science*, *118*, 273-274.
- Babcock, H., & Levy, L. (1930). An experiment in the measurement of mental deterioration. *Archives of Psychology*, *117*, 105-107.
- Bischof, M., & Bassetti, C. L. (2004). Total dream loss: A distinct neuropsychological dysfunction after bilateral PCA stroke. *Annals of Neurology*, *56*, 583-586.
- Braun, A. R., Balkin, T. J., Wesensten, N. J., Carson, R. E., Varga, M., Baldwin, P., Herscovitch, P. (1997). Regional cerebral blood flow throughout the sleep-wake cycle: An H2150 PET study. *Brain*, *120*, 1173-1197.
- Braun, A. R. (2000). Commentary on J. A. Hobson. The new neuropsychology of sleep: Implications for psychoanalysis. *This Journal*, *1* (2):196-201.
- Buzare, M., & Waisbord, P. (1983). Sleep and dreams in patients with parietal and frontal lesions. *Revue Neurologique*, *139*, 497-508.
- Cathala, H., Laffont, F., Siksou, M., Esnault, S., Gilbert, A., Minz, M., Moret-Chalmin, C., Charcot, J. M. (1883). Un cas de suppression brusque et isolee de la vision mentale des signes et des objets, (forms et couleurs) [On a case of sudden isolated suppression of the mental vision of signs and objects (forms and colours)]. *Progres Medical*, *11*, 568-571.
- Crick, F., & Mitchison, G. (1983). The function of dream sleep. *Nature*, *304*, 111-114.
- Critchley, M. (1953). *The parietal lobes*. London: Arnold.
- Damasio, H., & Damasio, R.D. (1989). *Lesion analysis in neuropsychology*. New York, Oxford: Oxford University Press.
- Doricchi, F., & Violani, C. (1992). Dream recall in brain damaged patients: A contribution to the neuropsychology of dreaming through a review of the literature. In J. Antrobus & M. Bertini (Eds), *The neuropsychology of sleep and dreaming* (pp. 99-140). Hillsdale, NJ: Lawrence Erlbaum Associates.
- Heiss, W. D., Pawlik, G., Herholz, K., Wagner, R., & Wienhard, K. (1985). Regional cerebral glucose metabolism in man during wakefulness, sleep and dreaming. *Brain Res*, *327*, 362-366.
- Hirshkowitz, M., & Sharafakhneh, A. (2009). Clinical polysomnography and the

- evolution of recording and scoring technique. In S. Chokroverty (Ed.), *Sleep disorders medicine: Basic science, technical considerations and clinical aspects* (pp. 229-52). Philadelphia, PA: Saunders Elsevier
- Hong, C. C. H., Gillin, J. C., Dow, B. M., Wu, J., & Buchsbaum, M. S. (1995). Localized and lateralised cerebral glucose metabolism associated with eye movements during REM and wakefulness: A positron emission tomography (PET). *Sleep*, 18, 570-580.
- Kaplan, E. F., Goodglass, H., & Weintraub, S. (2001). *The Boston Naming Test* (2nd ed.). Philadelphia: Lippincott William & Wilkins.
- Kosslyn, S. (1994). *Image and brain*. Cambridge, MA: MIT Press.
- Lezak, M. (1995). *Neuropsychological assessment* (3rd Ed.). New York: Oxford University Press.
- Maquet, P., Peters, J. M., Aerts, J., Delfiore, G., Degueldre, C., Luxen, A., & Franck, G. (1996). Functional neuroanatomy of human rapid-eye-movement sleep and dreaming. *Nature*, 383, 163-66.
- Murri, L., Arrena, R., Siciliano, G., Mazzotta, R., & Murarorio, A. (1984). Dream recall in patients with focal cerebral lesions. *Archives of Neurology*, 41, 183-185.
- Maquet, P., Peters, J. M., Aerts, J., Delfiore, G., Degueldre, C., Luxen, A., & Franck, G. (1996). Functional neuroanatomy of human rapid-eye-movement sleep and dreaming. *Nature*, 383, 163-66
- Nielsen, J. (1946). *Agnosia, apraxia, aphasia: Their value in cerebral localization* (2nd edition). New York: Hoeber.
- Nielsen, J. (1955). Occipital lobes, dreams and psychosis. *Journal of Nervous and Mental Disease*, 121, 50-52.
- Nofzinger, E. A., Mintun, M. A., Wiseman, M. B., Kupfer, D. J., & Moore, R. Y. (1997). Forebrain activation in REM sleep: An FDG PET study. *Brain Research*, 770, 192-201.
- Osterrieth, P. A. (1944). Le test de copie d'une figure complex: Contribution a l'étude de la perception et de la mémoire. *Archives de Psychologie*, 30, 286-356.
- Potzl, O. (1928). *Die Aphasielehre vom standpunkt der klinischen psychiatric, I: Die optisch agnoschen storungen (Die Verscheidenen Formen der Seelenblindheit)*[The aphasia doctrine from the standpoint of clinical psychiatry, I: Optic-agnosic disorders (the different forms of mind-blindedness)]. Leipzig: Deuticke

- Poza, J. J., & Martí Massó, J. F. (2006). Total dream loss secondary to left temporo-occipital brain injury. *Neurología*, 21, 152-154.
- Rey, A. (1941). L'examen psychologique dan les cas d'encephalophaie. *Archives de Psychologie*, 28, 286-340.
- Sivan, A. B. (1992). *Benton Visual Retention Test* (5th ed.). San Antonio, Tex.: The Psychological Corporation
- Solms, M., Kaplan-Solms, K., & Brown. (1996). Wilbrand's case of "mind-blindedness". In Code, C., Wallesch, C-W., Joannette, Y., & Lecours, A. R. (1996). Erlbaum, UK: Psychology Press.
- Solms, M. (1997). The neuropsychology of dreams: A clinico-anatomical study. Mahwah, NJ: Lawrence Erlbaum Associates.
- Solms, M. (2000a). Dreaming and REM sleep are controlled by different brain mechanisms. *Behavioral and Brain Sciences*, 23, 843-850.
- Solms, M. (2000b). Forebrain mechanisms of dreaming are activated from a variety of sources. *Behavioral and Brain Sciences*, 23, 1035-1040.
- Strauss, E., Sherman, E. M. S., & Spreen, O. (2006). *A compendium of neuropsychological tests: administration, norms, and commentary* (3rd ed.). New York: Oxford University Press.
- Walsh, K., & Darby, D. (2002). Neuropsychology: A clinical perspective. Edinberg, London: Churchill Livingstone.
- Wechsler, D. (1997). *WMS-III administration and scoring manual*. San Antonio, Tex., The Psychological Corporation.
- Yu, C. K. (2001). The neuroanatomical correlates of dreaming: The suprmarginal gyrus controversy (dream work). *Neuropsychanalysis*, 3, 47-59.
- Yu, C. K. (2007). A neuropharmacological study of dreaming in psychiatric patients. *Brain mechanisms of dreaming*, unpublished PhD Thesis: UCT.

Appendix A: Informed Consent Form

Title of research study: Do Dreams Protect Sleep? Testing the Freudian hypothesis of the function of dreams

Name of principal researcher: Catherine Cameron-Dow

Department/research group address: Psychology Department
Faculty of Humanities
University of Cape Town

Telephone: 021 650 3435

Email: cmrcat004@mail.uct.ac.za

Name of participant:

You are invited to take part in a research study for the Department of Psychology, at the University of Cape Town, in order to see whether suffering a stroke has had an effect on your dreams. Your participation is completely voluntary.

Participant's involvement:

What's involved: The study will involve spending two consecutive nights in a sleep laboratory. You will be connected to a polysomnograph, which is a simple sleep monitoring device that involves small pads being placed on different parts of your body (mainly your face and forehead). You will be asked to sleep as you usually would in your home environment. During the first night, you will be awakened twice by the researcher and asked whether you were dreaming. During the second night, you will not be awakened, and will just be required to sleep. During both nights, your sleep cycles will be recorded using a polysomnograph.

Risks: There are no risks associated with this study. However, if you feel uncomfortable at any time, for any reason, you may withdraw from the study without any negative consequences for yourself or the study. All data will be kept confidential and will only be used for research purposes.

Benefits: There are no direct benefits for participating in this study, except for monetary compensation (discussed below) and the possibility of detecting any sleep disorders that you may have.

Payment: As you would be giving up a considerable amount of your time, you will be paid R500 for each night that you complete in the sleep laboratory. Thus, if you complete the full two nights of the study you will receive R1000.

Please sign if you have read all the information and you agree to take part in the study.

Signature of Participant: _____

Name of Participant: _____

Signature of principal researcher: _____ (name)

Date: _____

Appendix B: Neuropsychological Tests

A range of neurocognitive tests were chosen for this study, focusing primarily on higher visual and spatial perception, visual and verbal short-term memory, and visual and audio-verbal long-term memory.

Visuo-spatial Perception

Luria's Neuropsychological Investigation. LNI-1 was used to assess higher visual perception and integration, and specifically included: 1) object recognition; 2) visual recognition of letters, words and phrases; 3) calculations; 4) colours and faces; 5) language (Christensen, 1974). The LNT-1 is designed not only to assess the general pattern of change in function after brain injury or damage, but to assess the neurodynamics changes underlying the change as well.

Judgement of Line Orientation Test. The JLO test was used to measure spatial perception and orientation (Benton et al., 1994). A card with 11 lines at different angles (making the shape of a semi-circle or fan) is presented to the participant, along with another card with only two lines on it. The participant is required to match the angle of the lines on a separate card with one of the 11 lines.

Facial Recognition Test. The purpose of the FRT was to assess the participant's ability to recognise unfamiliar human faces (Benton et al., 1994). The FRT uses photographs of faces (with the hair and clothing shaded out), and consists of three trials: First, the participant was required to identify a front-view photograph of a single face from a display of six front-view photographs of different faces; second, a front-view photograph had to be matched to 3 three-quarter-view photographs of the same face, that were mixed into a display of 6 three-quarter-view photographs; the third trial required the participant identify a single front-view photograph under different lighting conditions (within the photographs).

Boston Naming Test. Visual confrontation naming ability was assessed using the BNT-2 (Kaplan et al., 2001). The test is comprised of 60 line drawings and the participant is required to verbally identify each item. The line drawings are of objects that range from simple, frequently used words (e.g. comb) to words that are rare (e.g. abacus). In this study,

the BNT-2 was also used to test language ability and to ensure that the participant was not aphasic.

Constructional Praxis

WAIS-III Blocks. This subtest was chosen to assess perceptual organization and constructional praxis (Weschler, 1997a). The participant is required to use blocks to replicate models or pictures of two-colour designs.

Rey-Osterrieth Complex Figure. The ROCF test is used to assess visual-spatial constructional ability, immediate visual memory, and long-term visual memory (Rey, 1941; Osterrieth, 1944). The ROCF scoring system used was developed by Guyot and Rigault (1965) and includes scoring a copy trial, an immediate recall trial and a delayed recall trial after approximately 30 minutes. The participant was required to copy the figure as accurately as possible from the original drawing. She was required to finish in no more than 5 minutes. Immediately following the copy trial, she was required to draw the figure again from memory. A third recall trial was requested of her after a 30 minute delay.

Short-term memory

The subtests used to assess short term memory were all chosen from the Weschler Memory Scale (WMS-III; Weschler, 1997b).

Spatial Span. The Spatial Span was used to assess visual short-term memory. The subtest is comprised of two trials: First, the examiner touches a sequence of blocks and the participant is required to repeat the pattern in the same order. In the second trial, the participant is required to point to the blocks in the reverse order.

Digit Span. The Digit Span was used to test that the participant had intact audio-verbal short-term memory. The test required the participant to verbally repeat strings of digits of increasing length in the same order that she received them (forward) and the reverse order (backward).

Visual Reproduction 1. This subtest was used to assess visual short memory. During the test, the participant is shown an abstract figure for a brief amount of time (approximately

10 seconds) and is required to immediately reproduce it. The figures that the participant is required to reproduce become more complex after each successful trial.

Visual and verbal memory

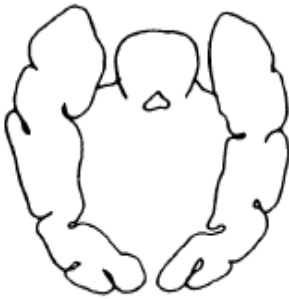Benton's Visual Retention Test. The BVRT-5 was used to assess long-term visual memory (Sivan, 1992). The test consists of 10 cards with geometric figures that increase in complexity (the last two cards include a smaller peripheral figure as well). The multiple choice version of the test was administered, where the participant had to choose the presented design from a four-card display. The multiple choice administration of this test is used to measure a participant's visual recognition.

The Babcock Story Test. This test was used for the evaluation of long-term verbal memory (Babcock, 1930; Babcock & Levy, 1940). A detailed story was narrated to the participant and she was then required to recall the details she could remember immediately after. The same story was then read a second time and the participant was again required to repeat all the story to the best of her ability.

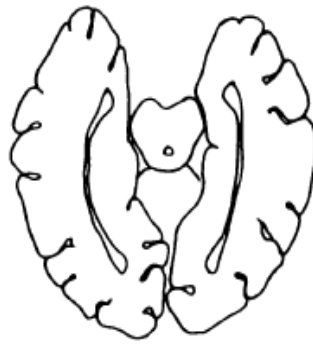The Bicycle Drawing Test. The BDT was included for the purpose of assessing revisualisation, and the participant was asked to draw a bicycle from memory, without the aid of a copy (Lezak, 1995).

Appendix C
Mrs A

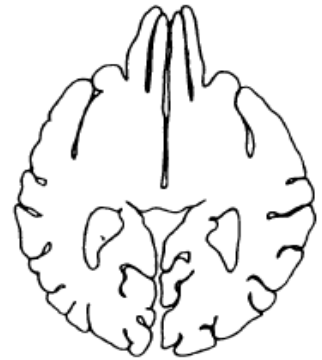
A



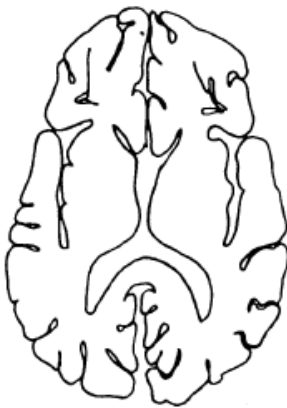B



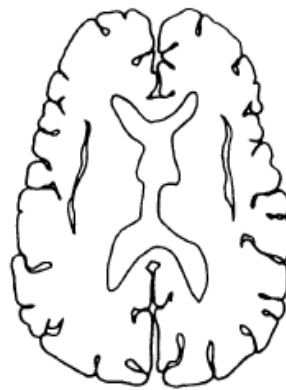C



D



E



F

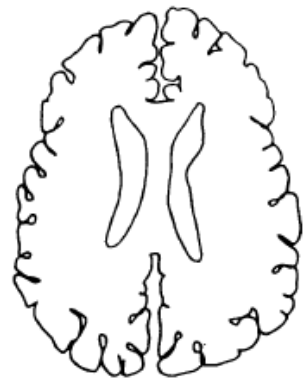
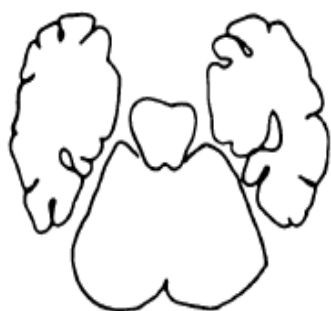

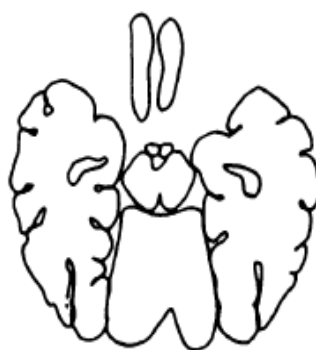Figure 1

Mrs C

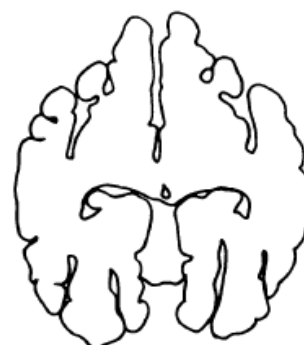A



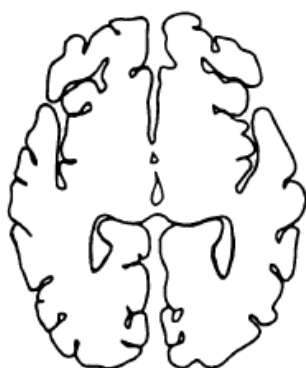B



C



D



E

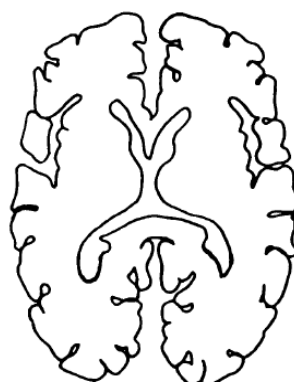
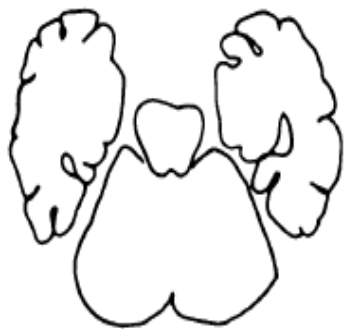

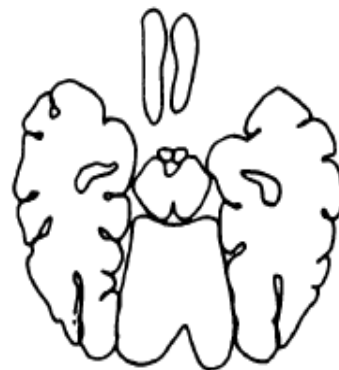Figure 2

Mr B

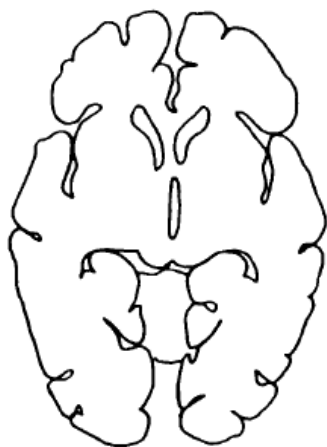A



B



C



D

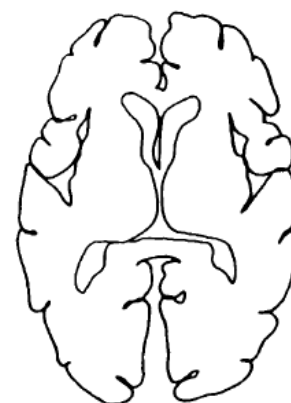
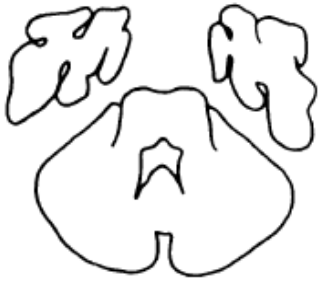
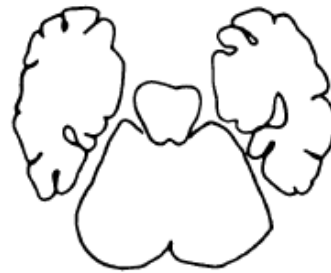Figure 3

Mrs J

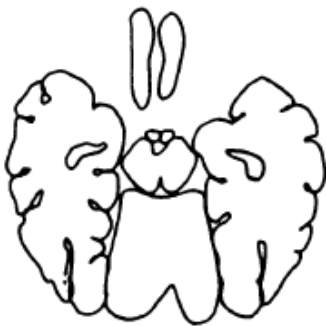A



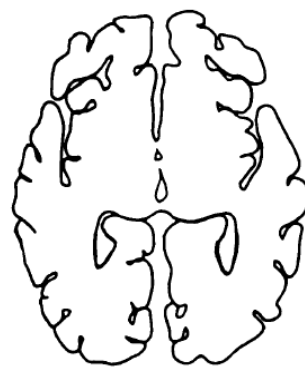
B



C



D



E

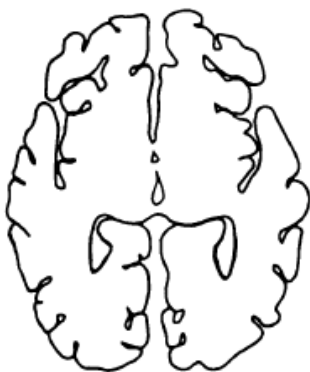

Figure 4

Mr R

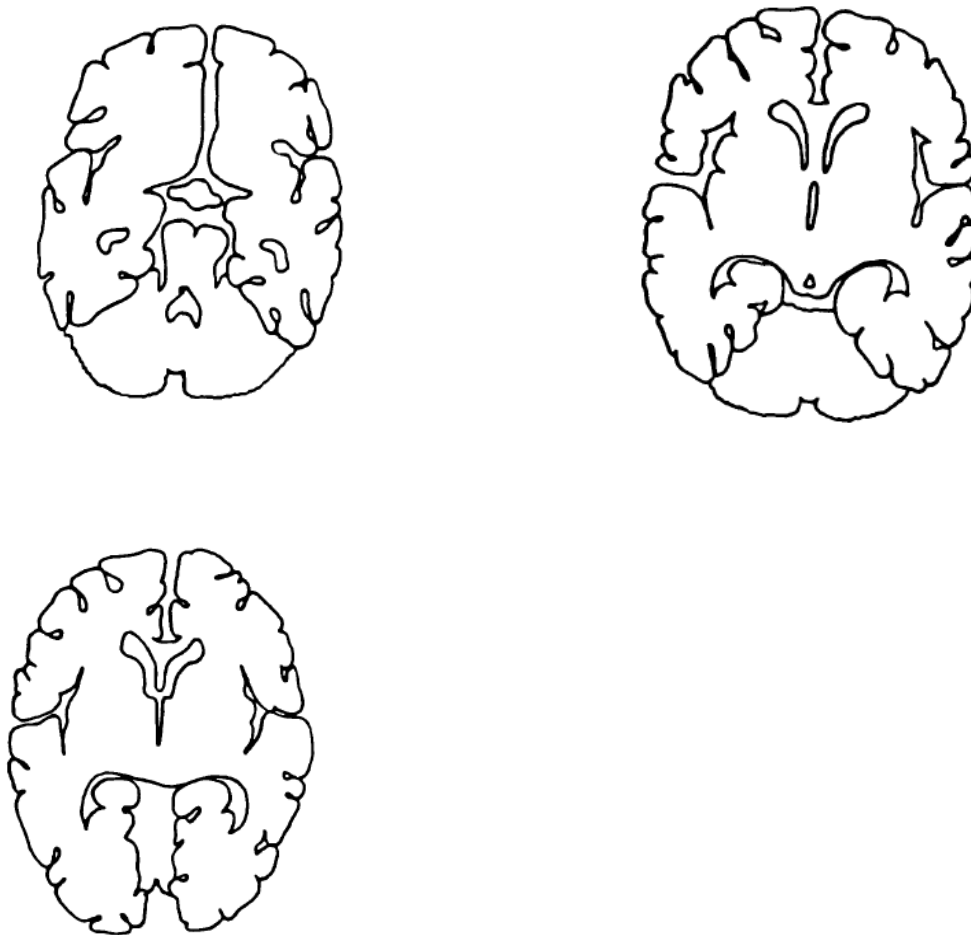


Figure 5